

Removal of a Cosmetic Femtosecond Laser-Assisted Keratopigmentation

Diego Castanera-Gratacós, MD; Sebastian Cerro-Clusella, MD; Fatima I. Sánchez-Aparicio, MD; César Gala-Núñez, OD, MSc

ABSTRACT

PURPOSE: To remove the maximum amount of pigment placed in the corneal stroma in a previous cosmetic femtosecond laser-assisted keratopigmentation procedure and restore visual function.

METHODS: Case report.

RESULTS: A 53-year-old man presented with bilateral cosmetic femtosecond laser-assisted keratopigmentation that resulted in decreased uncorrected and corrected distance visual acuity, poor visual quality, and increased corneal aberrations.

A femtosecond laser was used to create a corneal flap, followed by excimer laser ablation to remove stromal pigment within an 8.5-mm optical zone. This approach resulted in restoring corneal transparency with the regularization of corneal architecture, reduction in corneal aberrations, and elimination of induced ametropia, with subsequent improvement in visual acuity.

CONCLUSIONS: In cases requiring the reversal of femtosecond laser-assisted keratopigmentation, a combined femtosecond laser and excimer laser-assisted stromal ablation may effectively remove pigment restoring corneal transparency, reduce corneal aberrations, and improve visual acuity by addressing induced refractive error.

The increase in demand for cosmetic change of eye color has led to the development of procedures targeting various structures of the anterior segment, including intraocular prosthetics, YAG laser iris depigmentation, and keratopigmentation.¹ Femtosecond laser-assisted keratopigmentation (FLAK) has been developed as a new technique targeting the corneal stroma to obtain a cosmetic change of the eye color. This procedure involves the creation of an intrastromal annular ring that maintains a clear central corneal optical zone, followed by an injection of pigment into the stromal ring.^{2,3} Although pigment removal has been attempted with balanced salt solution (BSS) irrigation or mechanical scraping, no standardized or published method for effective reversal has been described.

We describe a patient who underwent FLAK for cosmetic reasons and later presented with visual disturbances such as glare, photophobia, and reduced quality of vision. We performed a combined femtosecond laser and

excimer laser procedure to address these problems and try to obtain both functional and cosmetic improvement.

CASE REPORT

A 53-year-old man presented to our clinic following a cosmetic FLAK procedure. The patient expressed regret over the aesthetic outcome and reported corneal and visual disturbances. Unsuccessful BSS irrigation had previously been attempted to remove the intrastromal pigment.

The patient had no significant medical history and reported no previous ocular pathology, aside from undergoing YAG laser iris depigmentation. Prior to the FLAK procedure, he described uncorrected distance visual acuity (UDVA) of 20/20 in both eyes and early presbyopia.

During the examination, UDVA was 20/25 in both eyes. Corrected distance visual acuity (CDVA) was 20/20⁻¹ in the right eye with +1.25 diopters (D) and 20/20⁻¹ in the left eye with +1.00 D. Uncorrected near vi-

From Tacir Clinic, Teknon Medical Center (Quirón Salud Group), Barcelona, Spain.

© 2025 Castanera-Gratacós, Cerro-Clusella, Sánchez-Aparicio, et al; licensee SLACK Incorporated. This is an Open Access article distributed under the terms of the Creative Commons Attribution-NonCommercial 4.0 International (<https://creativecommons.org/licenses/by-nc/4.0>). This license allows users to copy and distribute, to remix, transform, and build upon the article non-commercially, provided the author is attributed and the new work is non-commercial.

Disclosure: The authors have disclosed no potential conflicts of interest, financial or otherwise.

Address correspondence to Diego Castanera-Gratacós, MD, Carrer Vilana 12, Consulta 118, Barcelona 08022, Spain; email: d.castanera@clinicatacir.com.

Submitted: May 21, 2025. Accepted: October 28, 2025. Published online: December 1, 2025.

doi: 10.3928/1081597X-20251028-01

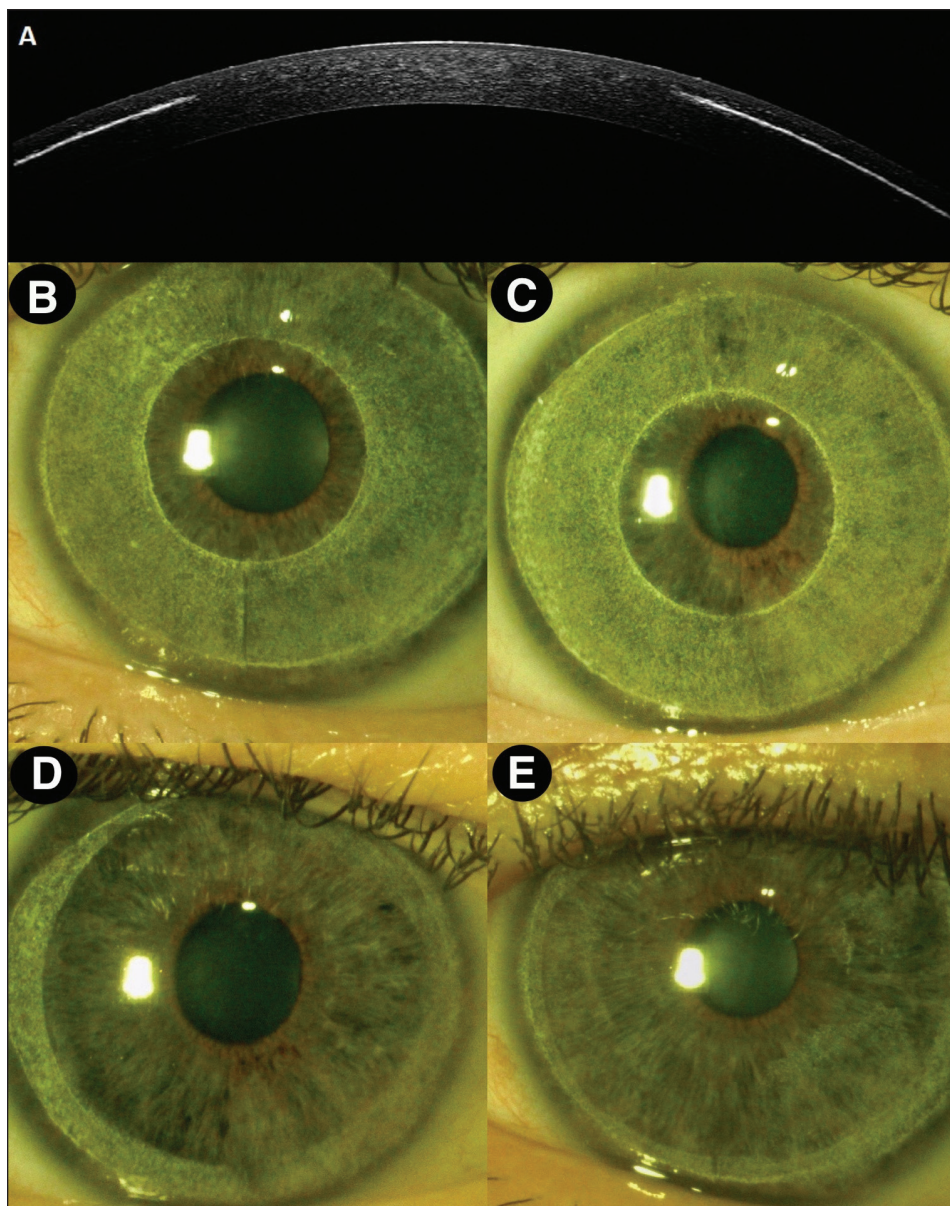


Figure 1. (A) Preoperative corneal optical coherence tomography of the right eye. (B) Preoperative slit-lamp photograph of the right eye. (C) Preoperative slit-lamp photograph of the left eye. (D) Postoperative slit-lamp photograph of the right eye. (E) Postoperative slit-lamp photograph of the left eye.

visual acuity (UNVA) measured at 40 cm was 20/32 in both eyes. Corrected near visual acuity (CNVA) was 20/20 in both eyes with a +1.50 D addition.

A deep intrastromal pigmented ring was noted in both eyes (**Figure 1**). Anterior segment module spectral-domain optical coherence tomography (Spectralis; Heidelberg Engineering) and corneal topography revealed pigment located at a depth of 175 μm , with an inner ring diameter of 5 mm and an outer ring diameter of 9.5 mm. Corneal topography demonstrated multiple irregularities and increased higher order aberrations (Pentacam AXL; Oculus Optikgeräte GmbH) (**Figure 2, Table 1**).

Due to the pigment's deep stromal migration, neither BSS irrigation nor mechanical scraping effectively removed it. Therefore, a combined femtosecond laser and

excimer laser approach was planned. A femtosecond laser (WaveLight FS200; Alcon Laboratories, Inc) was used to create a 9.6-mm diameter corneal flap with a thickness of 130 μm . To avoid the original incision site used for pigment injection, the flap hinge was positioned at 43° in the right eye and 140° in the left eye. An excimer laser (WaveLight EX500; Alcon Laboratories, Inc) was then used to ablate the pigmented stroma. A non-refractive, regular-depth phototherapeutic keratectomy was performed with an ablation zone of 8.9 mm. Stromal ablation depths were 60 μm in the right eye and 63 μm in the left eye. The profile was designed to produce a uniform stromal removal across the central 8.9 mm. Due to the depth, the refractive outcome was unpredictable; however, a myopic shift was anticipated based on previous studies.⁴

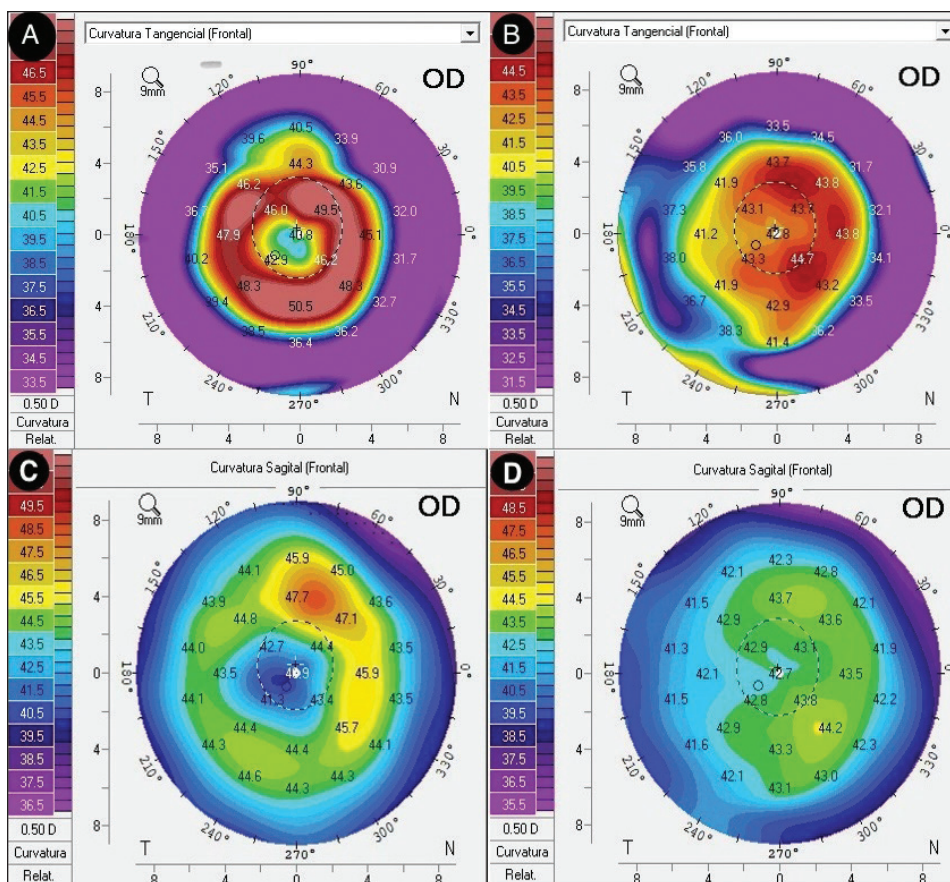


Figure 2. (A) Preoperative tangential map of the right eye. (B) Postoperative tangential map of the right eye. (C) Preoperative sagittal map of the right eye. (D) Postoperative sagittal map of the right eye.

TABLE 1
Corneal Aberrations

Parameter	Right eye (μm)		Left eye (μm)	
	Before surgery	After surgery	Before surgery	After surgery
Total RMS	7.631	2.035	7.631	3.749
RMS LOA	7.537	1.954	7.537	3.231
RMS HOA	1.195	0.568	1.195	1.900
Total corneal HOA (4 mm)	0.756	0.226	0.637	0.592
Z_4^0 total corneal (6 mm)	0.667	0.164	0.920	0.409

Abbreviations: HOA, higher order aberrations; LOA, lower order aberrations; RMS, root mean square; Z_4^0 , spherical aberration term of Zernike polynomials.

At the 24-hour follow-up visit, the pigmented stroma had been completely removed in the central 8.5-mm optical zone of the right eye. In the left eye, a small residual pigmented islet remained within the flap, whereas the rest of the central 8.5-mm optical zone was clear. Pigmentation persisted outside the ablation zone in both eyes, resembling arcus senilis.

At the 4-week follow-up visit, UDVA was 20/20 in both eyes (Figure 3). UNVA measured at 40 cm was 20/25. CNVA was 20/20 with a +1.75 D addition in both eyes. Topographic improvement of the anterior corneal irregularities was observed (Figure 2), with reduction of cor-

neal aberrations (Table 1). Corneal clarity was restored in the central 8.5-mm optical zone (Figure 1). Subjective visual quality was notably improved.

DISCUSSION

When treating patients who regret undergoing FLAK, different options can be considered. In this case, the pigment was introduced at a depth of 175 μm and had already migrated into deeper stromal layers, which explains why the BSS irrigation and mechanical scraping proved ineffective. The combined femtosecond laser and excimer laser approach was superior because it allowed

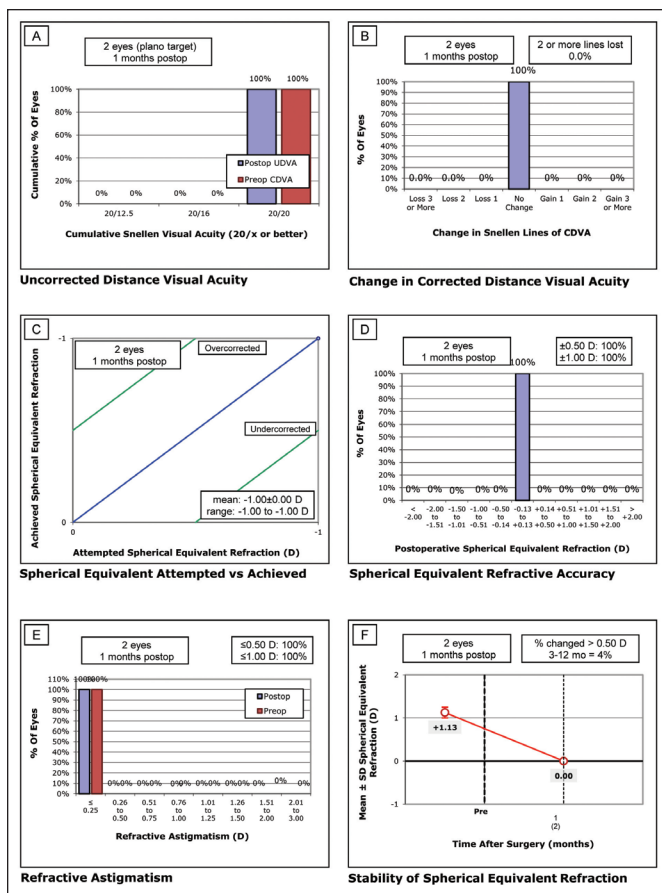


Figure 3. Standard graphs showing (A) uncorrected distance visual acuity (UDVA), (B) change in corrected distance visual acuity (CDVA), (C) spherical equivalent attempted versus achieved, (D) spherical equivalent accuracy, (E) refractive astigmatism, and stability of spherical equivalent refraction. D, diopters.

for precise lamellar access with a controlled flap, followed by a uniform stromal ablation, removing the pigment that remained inaccessible.

Beyond pigment elimination, there was an improvement in subjective visual quality and the reduction in corneal higher order aberrations. Glare, photophobia, and irregular astigmatism are documented sequelae of keratopigmentation, resulting from disruption of corneal transparency and induction of optical aberrations. By clearing the central 8.5-mm optical zone, this procedure addressed the main cause of such disturbances and restored both corneal regularity and transparency.

Refractive outcomes require particular consideration. Phototherapeutic keratectomy is known to induce refractive shifts, depending on ablation depth, optical zone diameter, and the excimer laser platform used. In our case, the ablation profile was designed to be non-refractive, yet the removal of irregular stromal tissue led

to the elimination of the hyperopia and improved CDVA. The anticipated myopic shift described in the literature caused by the external diameter transition zone in this excimer laser platform explained these refractive changes. Because it depends on the depth and ablation zone, the refractive changes will be unpredictable.

Stability of pigment removal is uncertain, but is unlikely to cause a migration of pigment from the remaining outer ring to the central clear cornea. Risk of stromal haze or scarring remains, similar to other refractive surgeries performed at the same depth. Follow-up is essential to confirm the durability of corneal clarity.

This case report describes a single patient, and therefore the generalizability of outcomes is limited. Not all patients will present with comparable pigment depth or distribution, and results may vary depending on the equipment used, surgical planning, and individual corneal biology. Larger case series are needed to establish the reproducibility of this technique.

CONCLUSION

Our findings suggest that when BSS irrigation or mechanical scraping fail, a combined femtosecond laser and excimer laser procedure can provide an effective alternative for pigment removal in cosmetic keratopigmentation. This technique restores corneal transparency, reduces optical aberrations, and improves visual acuity, offering both functional and cosmetic benefits.

AUTHOR CONTRIBUTIONS

Study concept and design (DC-G, FIS-A); data collection (DC-G, SC-C, CG-N); analysis and interpretation of data (DC-G, FIS-A, CG-N); writing the manuscript (DC-G, FIS-A); critical revision of the manuscript (DC-G, SC-C, FIS-A, CG-N)

REFERENCES

1. D'Oria F, Abu-Mustafa SK, Alió JL. Cosmetic change of the apparent color of the eye: a review on surgical alternatives, outcomes and complications. *Ophthalmol Ther.* 2022;11(2):465-477. <https://doi.org/10.1007/s40123-022-00458-2> PMID:35061240
2. Alió J, Sanginabadi A, Hojabr AT, Jafari B. Femtosecond laser-assisted keratopigmentation outcomes for pure cosmetic purposes. *Am J Ophthalmol Case Rep.* 2025;38:102297. <https://doi.org/10.1016/j.ajoc.2025.102297>
3. Hashemian SJ, Roozdar S, Alió JL. Therapeutic keratopigmentation: cosmetic and functional outcomes. *Ophthalmol Ther.* 2025;14(5):1133-1145. <https://doi.org/10.1007/s40123-025-01131-0> PMID:40178761
4. Tobalem S, Panthier C, Moran S, Debellemanni G, Gatinel D. Myopic outcomes after excimer laser phototherapeutic keratectomy (PTK). *J Fr Ophthalmol.* 2021;44(1):35-40. <https://doi.org/10.1016/j.jfo.2020.03.024> PMID:33158609